

Title: Updates in Canine Mitral Valve Disease Part 2

Session description:

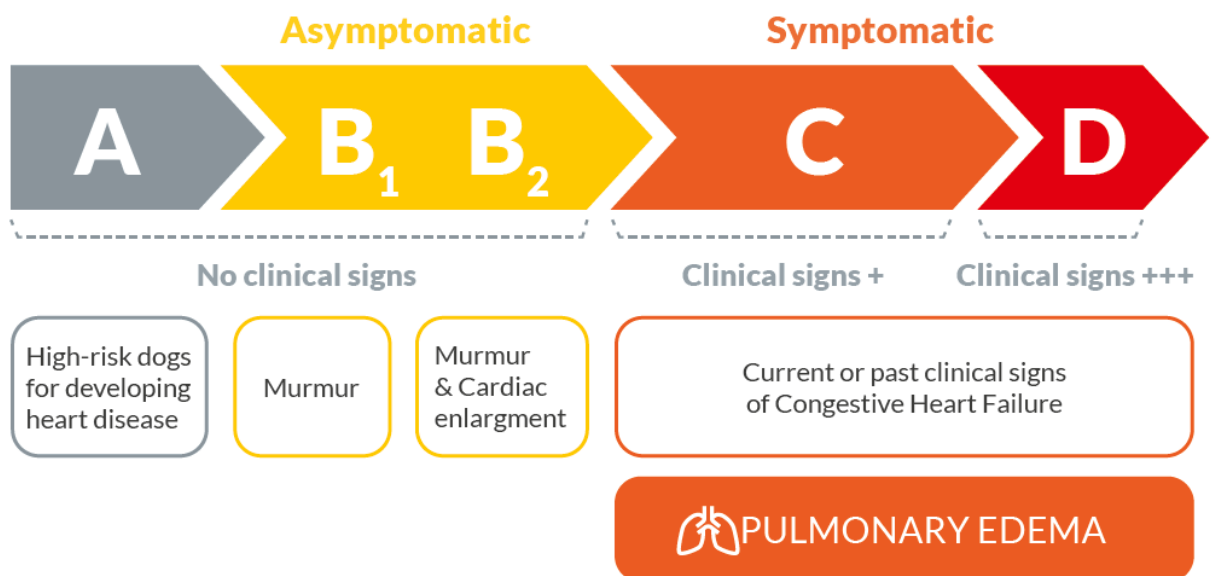
This presentation will be a practical review of the 2019 ACVIM consensus guidelines for myxomatous mitral valve disease (MMVD) in dogs. We will discuss using the recommended classification system in practice as well as how to streamline your diagnostic and treatment recommendations for your MMVD patients. The 2019 ACVIM treatment guidelines recommend a quad-therapy approach. We will discuss why and what that means for your MMVD patients.

Lecture notes:

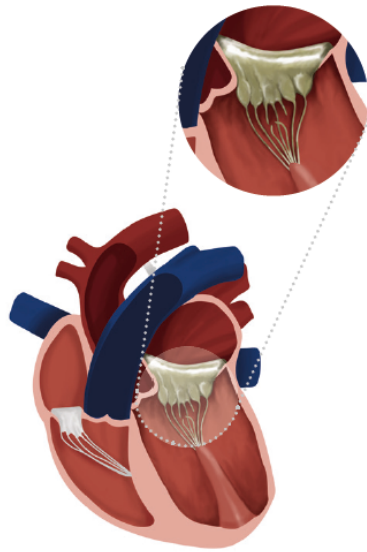
Published in 2019, the revised ACVIM consensus guidelines for the diagnosis and treatment of MMVD in dogs contains updates to the diagnostic, medical, surgical, and dietary treatment recommendations that were last published in 2009.

The significant recommendation updates include the use of a positive inotrope in stage B2 and the addition of spironolactone to CHF management in stages C and D. Rather than the traditional use of triple-therapy (furosemide, ACEI, pimobendan) for the CHF patient, a quad-therapy approach (furosemide, ACEI, pimobendan, **spironolactone**) is now recommended.

Classification of MMVD Stages:



Diagnosis:



Heart with MMVD



Compensated phase

- › No clinical signs
- › Cardioremodeling incl. enlargement detected by radiograph or echocardiography



Examinations

Criteria to be met before treatment initiation:

- › Auscultation: Murmur $\geq 3/6$
- › Echocardiography:
 - LA/Ao ≥ 1.6
 - LVIDDn ≥ 1.7
- › Thoracic radiograph
 - VHS > 10.5
 - If no echo available: VHS ≥ 11.5
- › Blood pressure measurement



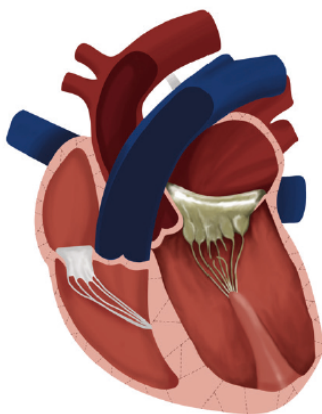
Decompensated phase

- › Current or past clinical signs of left-sided Congestive Heart Failure:
 - Tachypnea
 - Activity intolerance
 - Respiratory distress
 - Cough

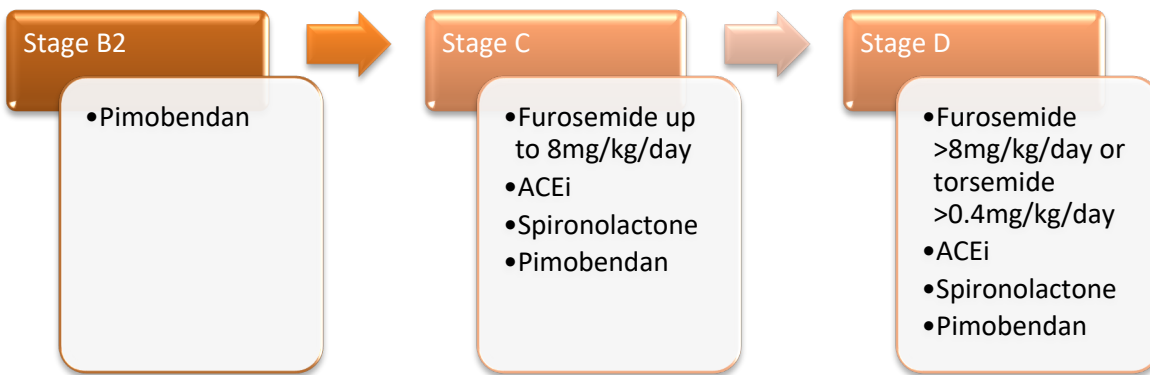


Examinations

- › Auscultation
- › Thoracic radiograph
- › Echocardiography
- › Blood testing incl. Serum total protein, Creatinine, BUN & electrolytes concentrations
- › Serum NT-proBNP
- › Blood pressure measurement



Treatment:



References:

- Keene, BW, Atkins, CE, Bonagura, JD, et al. ACVIM consensus guidelines for the diagnosis and treatment of myxomatous mitral valve disease in dogs. *J Vet Intern Med.* 2019; 33: 1127– 1140. <https://doi.org/10.1111/jvim.15488>
- Borgarelli M, Häggström J. Canine degenerative myxomatous mitral valve disease: natural history, clinical presentation and therapy. *Vet Clin North Am Small Anim Pract.* 2010; 40:651-663.
- Häggström J, Höglund K, Borgarelli M. An update on treatment and prognostic indicators in canine myxomatous mitral valve disease. *J Small Anim Pract.* 2009; 5:25-33.
- Lantis A, Atkins C, Defrancesco T, Keen B, Weere S. Effects of furosemide and the combination of furosemide and the labeled dosage of pimobendane on the circulating renin-angiotensin-aldosterone system in clinically normal dogs. *Am J of Vet Research* 2011; 72. 1646-51. 10.2460/ajvr.72.12.1646.
- Pitt B. "Escape" of aldosterone production in patients with left ventricular dysfunction treated with an angiotensin converting enzyme inhibitor: implications for therapy. *Cardiovasc Drugs Ther.* 1995;9(1):145-149. doi:10.1007/BF00877755
- Ames MK, Atkins CE, Eriksson A, Hess AM. Aldosterone breakthrough in dogs with naturally occurring myxomatous mitral valve disease. *J Vet Cardiol.* 2017;19(3):218-227. doi:10.1016/j.jvc.2017.03.001
- Ames MK, Atkins CE, Pitt B. The renin-angiotensin-aldosterone system and its suppression [published correction appears in *J Vet Intern Med.* 2019 Sep;33(5):2551]. *J Vet Intern Med.* 2019;33(2):363-382. doi:10.1111/jvim.15454

- Freedom of Information Summary, NADA #141-538 (July 27, 2020)